



# **SVC SYNDROME: INDUCTION AND INTUBATION IN THE ICU FOR URGENT STENT PLACEMENT**

**Rachel E. Corbitt M.D., (Jeffrey Huang, MD, MS)**

**2022 MINNESOTA SOCIETY OF ANESTHESIOLOGISTS (MSA) ANNUAL CONFERENCE**  
November 19-20, 2022 – Bloomington, MN

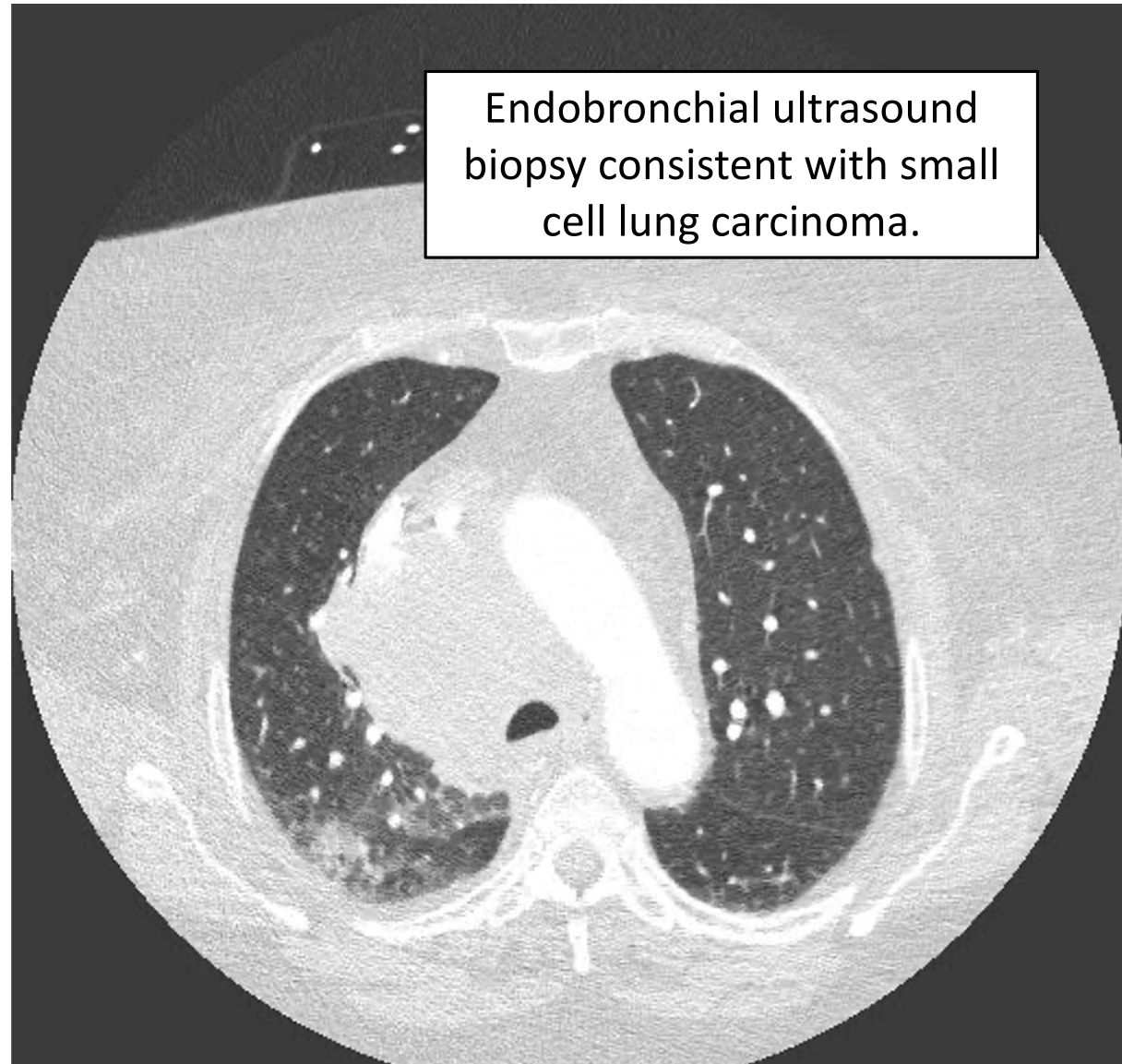
66 yo female, PMHx of COPD, asthma, 40 pack-years, HLD, ADHD, depression, and BMI 37 presented with two weeks of **progressive dyspnea with activity, fatigue, and facial and upper extremity swelling.**

**Physical exam:**

- Bilateral upper extremity edema, radial pulses intact, face and neck erythema, scattered ecchymosis of upper extremities.
- SpO2 in the low 90s.
- Awake and mentating appropriately.

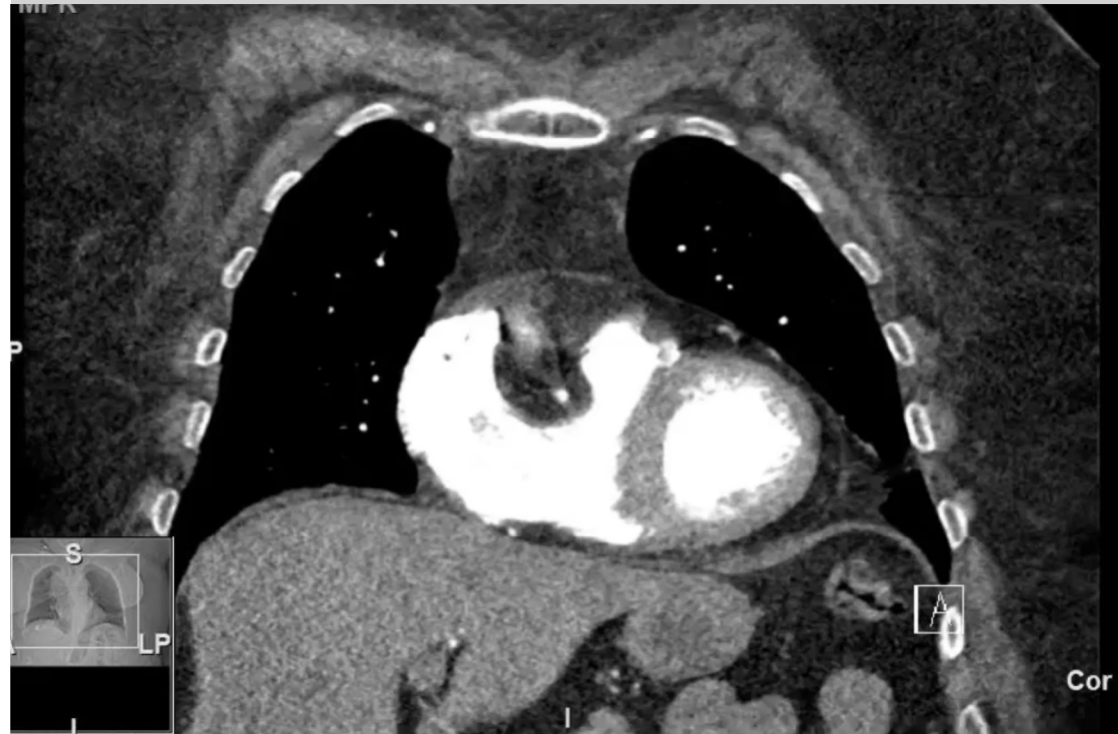**CT chest angiogram in the ED:**

- “Purple” laying flat in CT with SpO2 in 60s
- 9.5 x 6.2 x 7.2 cm soft tissue mass
- Invasion of the SVC without complete occlusion
- No definite invasion of the trachea



# SVC SYNDROME

- Obstruction to blood flow through the SVC → SVC syndrome
- Causes: mediastinal tumor, thrombus, stenosis
- Presentation:
  - Upper extremity, face, neck, and oropharyngeal swelling, conjunctival edema
  - Dilation of collateral veins in the thorax and neck
  - Dyspnea, cough, orthopnea
  - Severe symptoms: confusion, somnolence, hypotension, stridor



Initially admitted to ICU given small pressor requirement, but transferred to general medicine the following day.

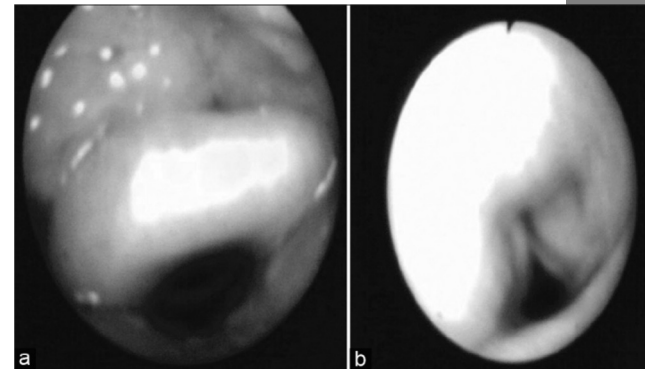
- SVC venography & stenting deferred (inability to lay flat or hold breath)...
- Urgent transfer to ICU with increased work of breathing, cyanosis, hypoxia to the 70s, somnolence

## INTUBATION IN THE ICU

- Goal: Fiberoptic intubation with conscious sedation + topicalization with 4% lidocaine nebulizer
- First attempt: Significant pharyngeal edema. Passage of scope through the vocal cords complicated by laryngospasm and desaturation requiring two-handed bag mask ventilation.
- Second attempt (with more sedation and topicalization): uncomplicated, tube positioned 4 cm above the carina
- Total sedatives used: midazolam 5 mg, fentanyl 200 mcg, ketamine 140 mg (through IO line)
- After intubation, sedation with propofol and fentanyl
- Paralyzed with vecuronium 10 mg for ventilator synchronization and to assist with SVC stent procedure (breath holds)

# ANESTHESIA CONCERNS FOR SVC SYNDROME

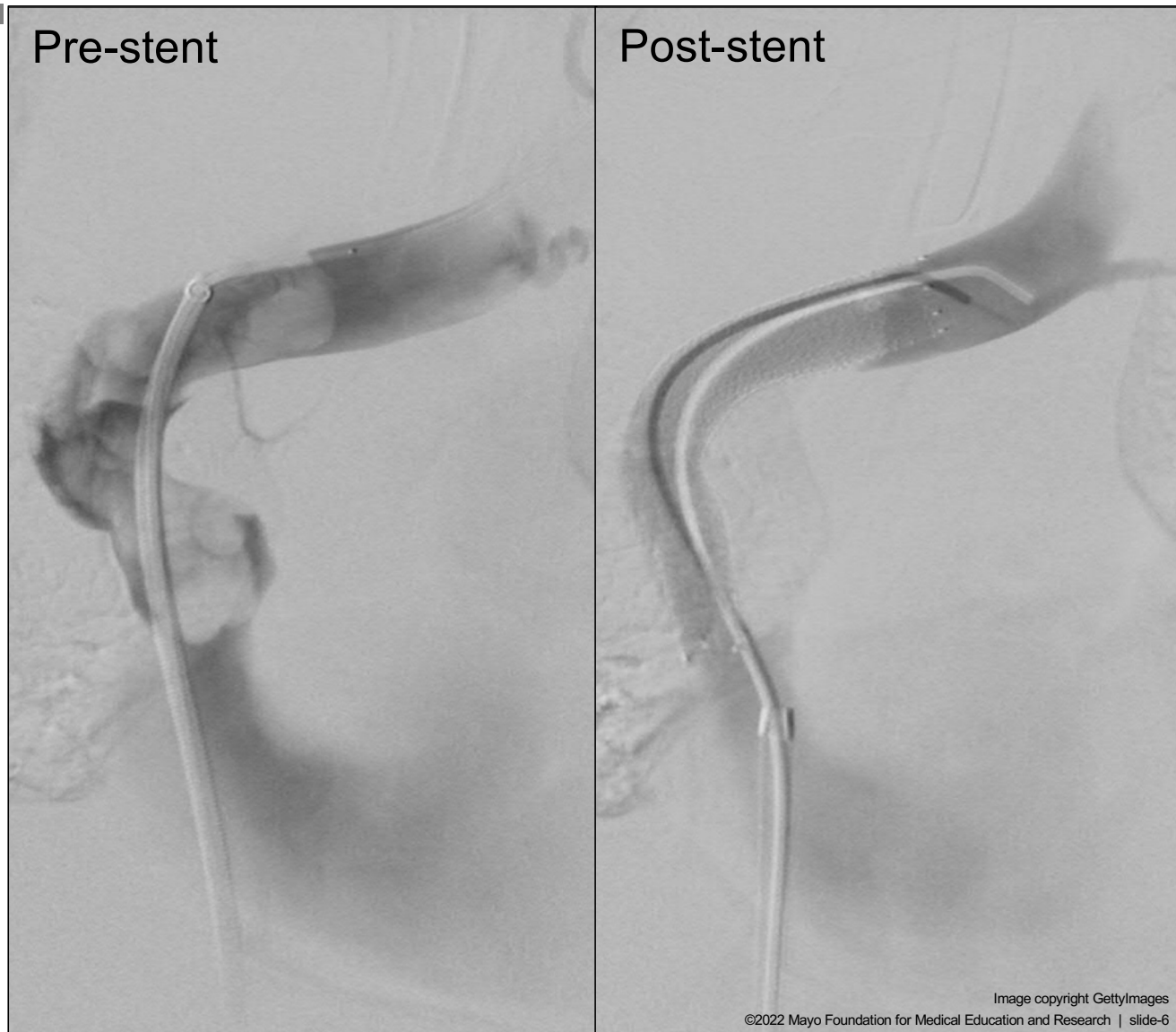- Maintain spontaneous ventilation:
  - Sedatives and muscle relaxants → risk loss of airway patency
    - Oropharyngeal edema, obstruction from mass = difficulty visualizing glottis during DL
  - PPV → high intrathoracic pressures → reduced preload
- Awake fiberoptic intubation:
  - Ensure tube is placed beyond tracheal obstruction
  - Avoid airway trauma (↑ risk of airway bleeding given venous engorgement)
- Have the patient sitting up:
  - Reduce airway edema
  - Supine → mass shifting can compress airway and great vessels
    - Try laying the patient flat during your pre-op exam to assess
- Ensure reliable IV access:
  - Upper extremity edema and sluggish circulation proximal to SVC obstruction
  - Place IVs in lower extremities
- Femoro-femoral CPB established under local anesthesia
  - Mediastinal mass may distort airway such that successful fiberoptic intubation is unlikely



Chaudhary et al., Anesthetic management of superior vena cava syndrome due to anterior mediastinal mass. *J Anaesthesiol Clin Pharmacol.* 2012;28(2):242-246.

# VENOGRAM AND STENTING

“Malignant obstruction of the SVC extending into the innominate veins treated with a 13 mm x 10 cm Viabahn self-expanding covered stent from the large caliber left innominate vein to the upper right atrium. Pressure gradient decreased from 19 mmHg to 3 mmHg.”



# SOURCES

- Chaudhary K, Gupta A, Wadhawan S, Jain D, Bhadoria P. Anesthetic management of superior vena cava syndrome due to anterior mediastinal mass. *J Anaesthesiol Clin Pharmacol*. 2012;28(2):242-246. doi:10.4103/0970-9185.94910
- Dishman D. Anesthetic Implications of Superior Vena Cava Syndrome in Interventional Radiology: A Case Report. *AANA J*. 2017 Dec;85(6):453-459. PMID: 31573505
- Said SM, Telesz BJ, Makdisi G, Quevedo FJ, Suri RM, Allen MS, Mauermann WJ. Awake cardiopulmonary bypass to prevent hemodynamic collapse and loss of airway in a severely symptomatic patient with a mediastinal mass. *Ann Thorac Surg*. 2014 Oct;98(4):e87-90. doi: 10.1016/j.athoracsur.2014.06.104. PMID: 25282247.
- Seligson MT, Surowiec SM. Superior Vena Cava Syndrome. [Updated 2021 Jul 13]. In: StatPearls [Internet]. Treasure Island (FL): StatPearls Publishing; 2022 Jan-. Available from: <https://www.ncbi.nlm.nih.gov/books/NBK441981/>
- Sendasgupta C, Sengupta G, Ghosh K, Munshi A, Goswami A. Femoro-femoral cardiopulmonary bypass for the resection of an anterior mediastinal mass. *Indian J Anaesth*. 2010;54(6):565-568. doi:10.4103/0019-5049.72649
- Slinger, Petera; Karsli, Cengizb Management of the patient with a large anterior mediastinal mass: recurring myths, *Current Opinion in Anaesthesiology*: February 2007 - Volume 20 - Issue 1 - p 1-3 doi: 10.1097/ACO.0b013e328011390b
- Totonchi Z, Givtaj N, Sakhaei M, et al. Anesthetic Management in a Patient With Type A Aortic Dissection and Superior Vena Cava Syndrome. *Res Cardiovasc Med*. 2015;4(3):e27424. Published 2015 Aug 1. doi:10.5812/cardiovascmed.27424v2

## Q&A

