

Vagus Nerve Stimulator placement in an adult with Dyke-Davidoff-Masson Syndrome

Jason Srnec M.D., Brian McGlinch, M.D.

University of Minnesota – Minneapolis, Minnesota

MSA 2022



MEDICAL SCHOOL | UNIVERSITY OF MINNESOTA

CASE DESCRIPTION:

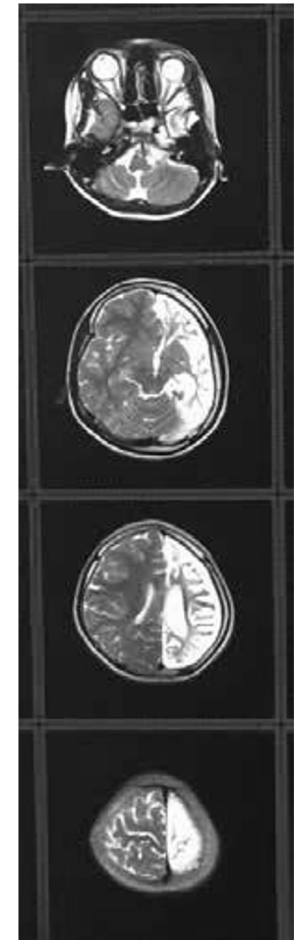
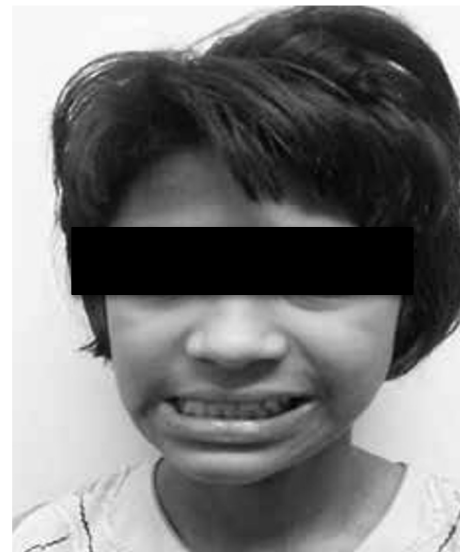- 41-year-old female
- Past medical history:
 - Dyke-Davidoff-Masson Syndrome
 - Intractable epilepsy – Clobazam, Modafinil, Levetiracetam, Lacosamide, Zonisamide
- Over 100 seizures in 2020
- Declined lesionectomy
- Procedure: Vagus nerve stimulator placement for intractable epilepsy



MEDICAL SCHOOL | UNIVERSITY OF MINNESOTA

DYKE-DAVIDOFF-MASSON SYNDROME:

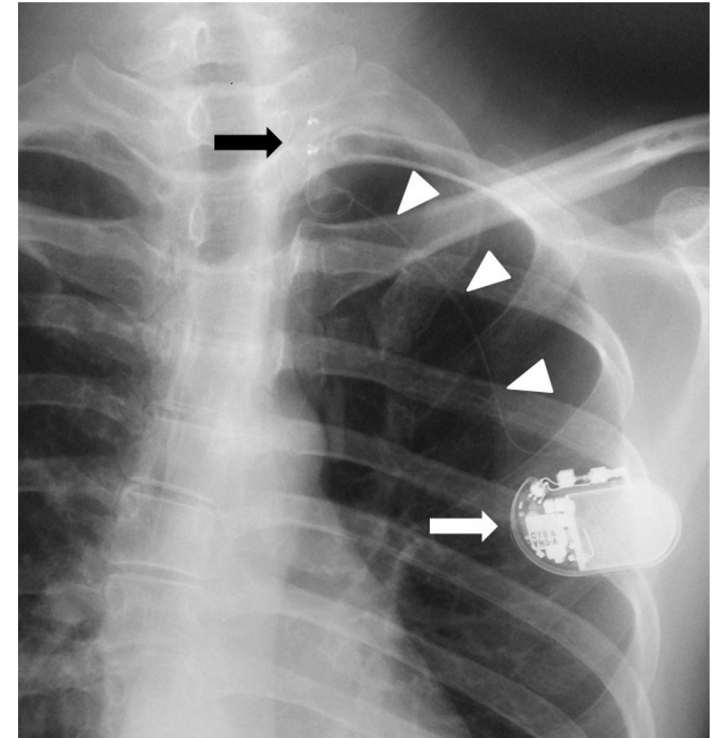
- Rare neurologic disorder
- Can affect children and adults
- Involvement of multiple systems



MEDICAL SCHOOL | UNIVERSITY OF MINNESOTA

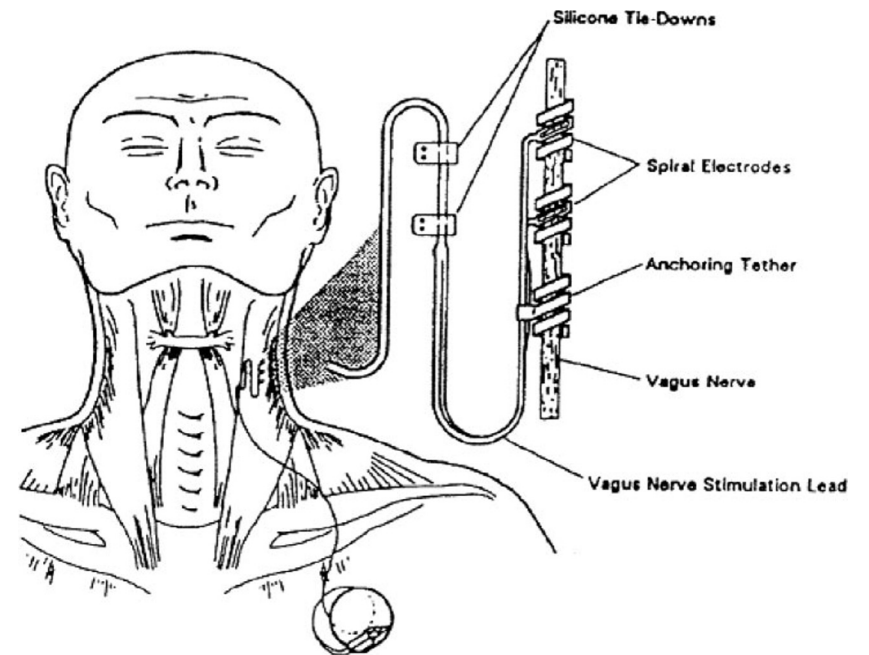
VAGUS NERVE STIMULATOR:

- Alternative treatment method for epilepsy
- Exact mechanism of action unknown
- Placement performed under general anesthesia



VNS CONSIDERATIONS:

- Medications
- Risk of hemorrhage
- Reduce risk of seizure
- Postoperative complications
- Additional surgery/imaging



Conclusions:

- Dyke-Davidoff-Masson Syndrome has significant anesthetic implications including ability to consent, potential for difficult airway, concern for occult myopathy, and high seizure risk
- With vagus nerve stimulator placement anticipate the possibility of seizure activity, and hemorrhage along with potential postoperative peritracheal hematoma and hoarseness

References:

1. Hatton, Kevin W. MD; McLarney, J Thomas MD; Pittman, Thomas MD; Fahy, Brenda G. MD, FCCM Vagal Nerve Stimulation: Overview and Implications for Anesthesiologists, *Anesthesia & Analgesia*: November 2006 - Volume 103 - Issue 5 - p 1241-1249 doi: 10.1213/01.ane.0000244532.71743.c6
2. Bagle A, Nagdev T, Chadha G, Amonkar J. Anesthetic considerations in patients with Dyke-Davidoff-Masson syndrome: a case report and review of literature. *Anaesthesia Pain & Intensive Care* 2017;21(1):105-108



MEDICAL SCHOOL | UNIVERSITY OF MINNESOTA